SE 20

OVERVIEW OF THE FIVE STUDIES

PURPOSE

This exhibit examines the pitfalls of i) the commonly-used radiographic methods for measuring limb, knee, femoral, and tibial joint line alignment, ii) two gap-balancing alignment methods in total knee arthroplasty (TKA), and iii) mechanical alignment with three rotational methods for aligning the femoral component in TKA.

CONSIDERATIONS FOR MEASURING CORONAL ALIGNMENT

STUDY 1 How Does Limb Rotation and Flexion Contracture of the Knee Change Four Measurements of Coronal Alignment?

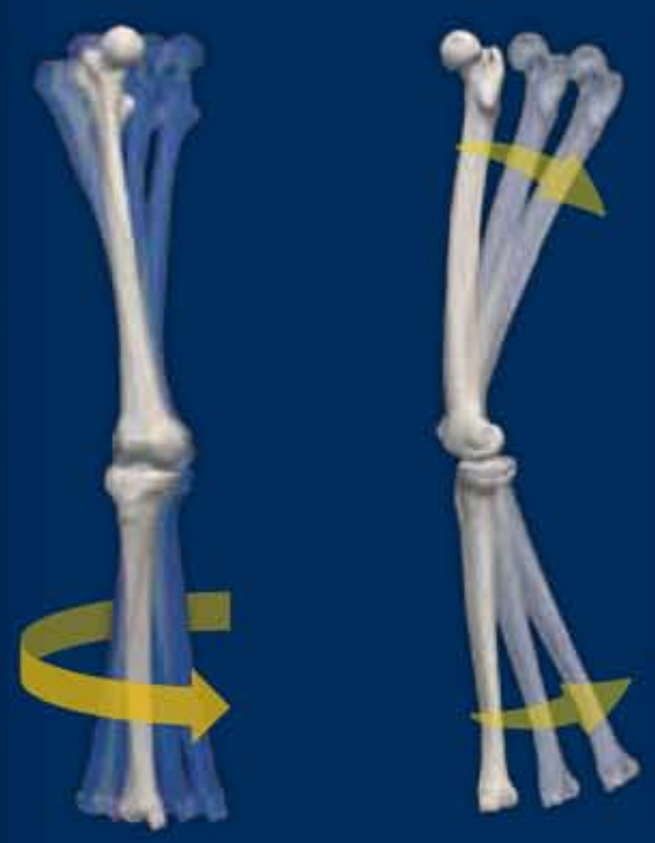

STUDY 2 How Frequently Do Three Radiographic Methods for Rotationally Aligning the Limb Change the Measurements of Coronal Alignment?

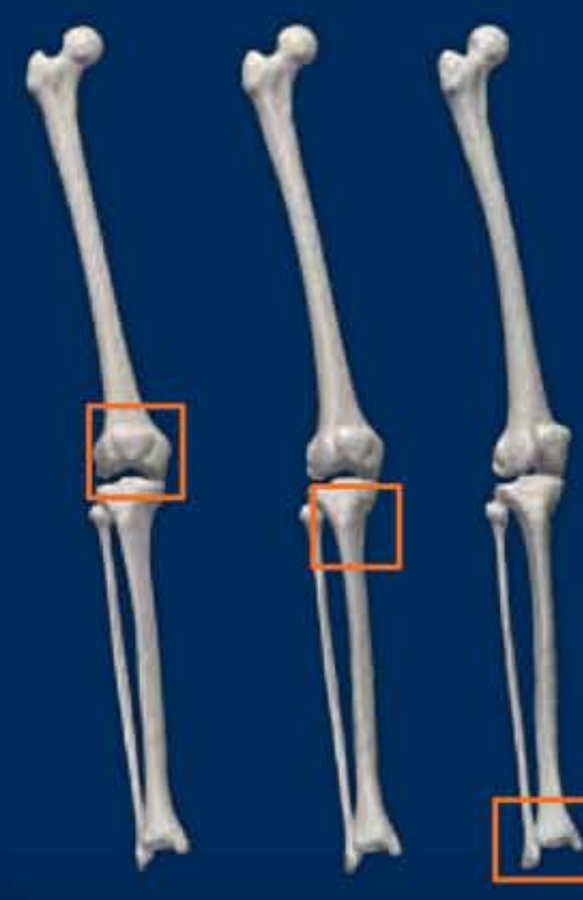

STUDY 3 How Frequently Does the Classification of Limb and Knee Alignment as Either 'In-range', Varus 'Outlier', or Valgus 'Outlier' Disagree in a Normal Limb?

SIMULATIONS OF SURGICAL ALIGNMENT TECHNIQUES

STUDY 4 How Frequently Do Two Gap Balancing Methods Change the Joint Lines and Limb Alignment from Normal in TKA?

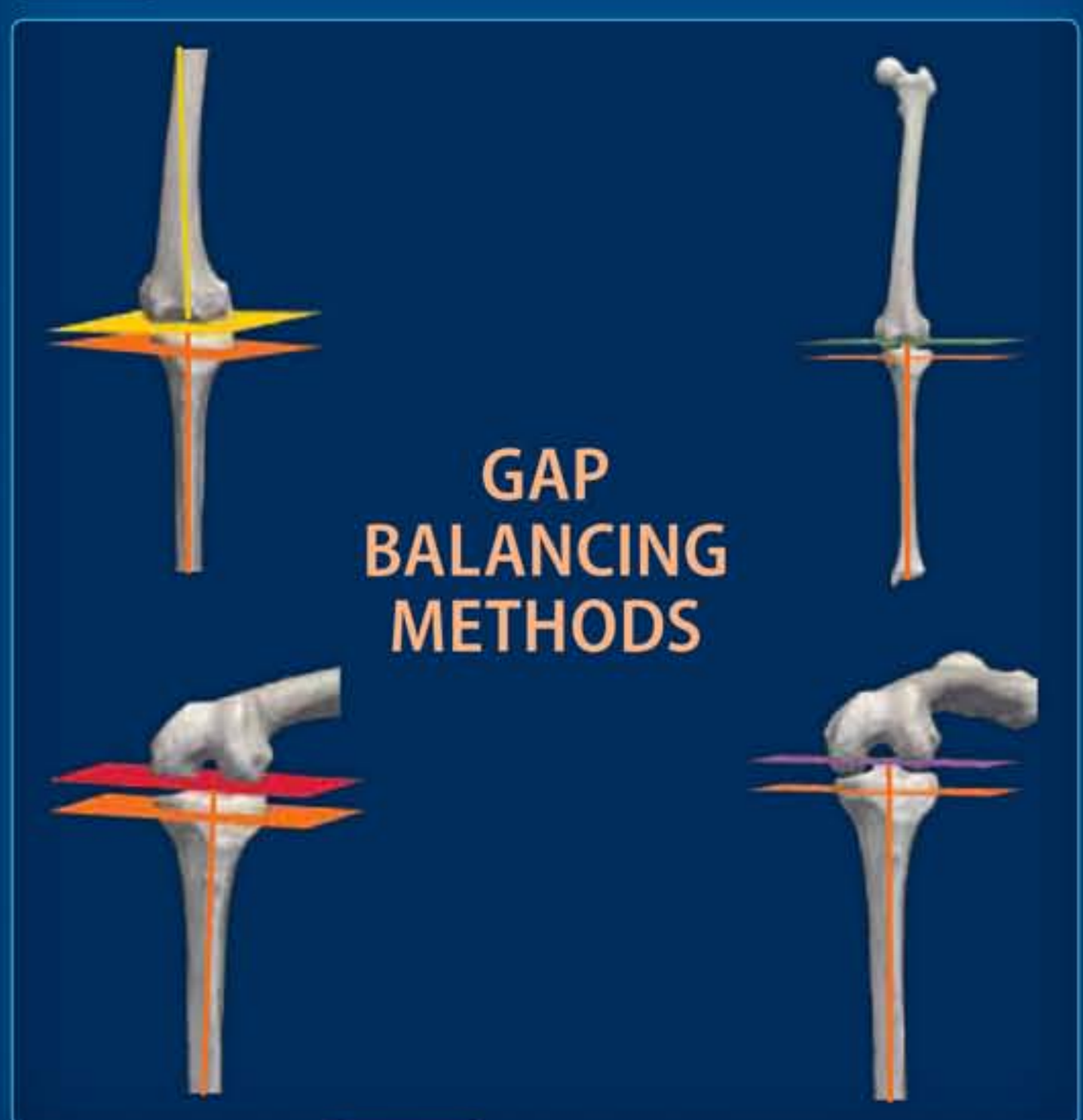

STUDY 5 How Frequently does Mechanical Alignment with Three Rotational Methods Change Joint Lines, Change Limb Alignment, and Cause Instability in TKA?

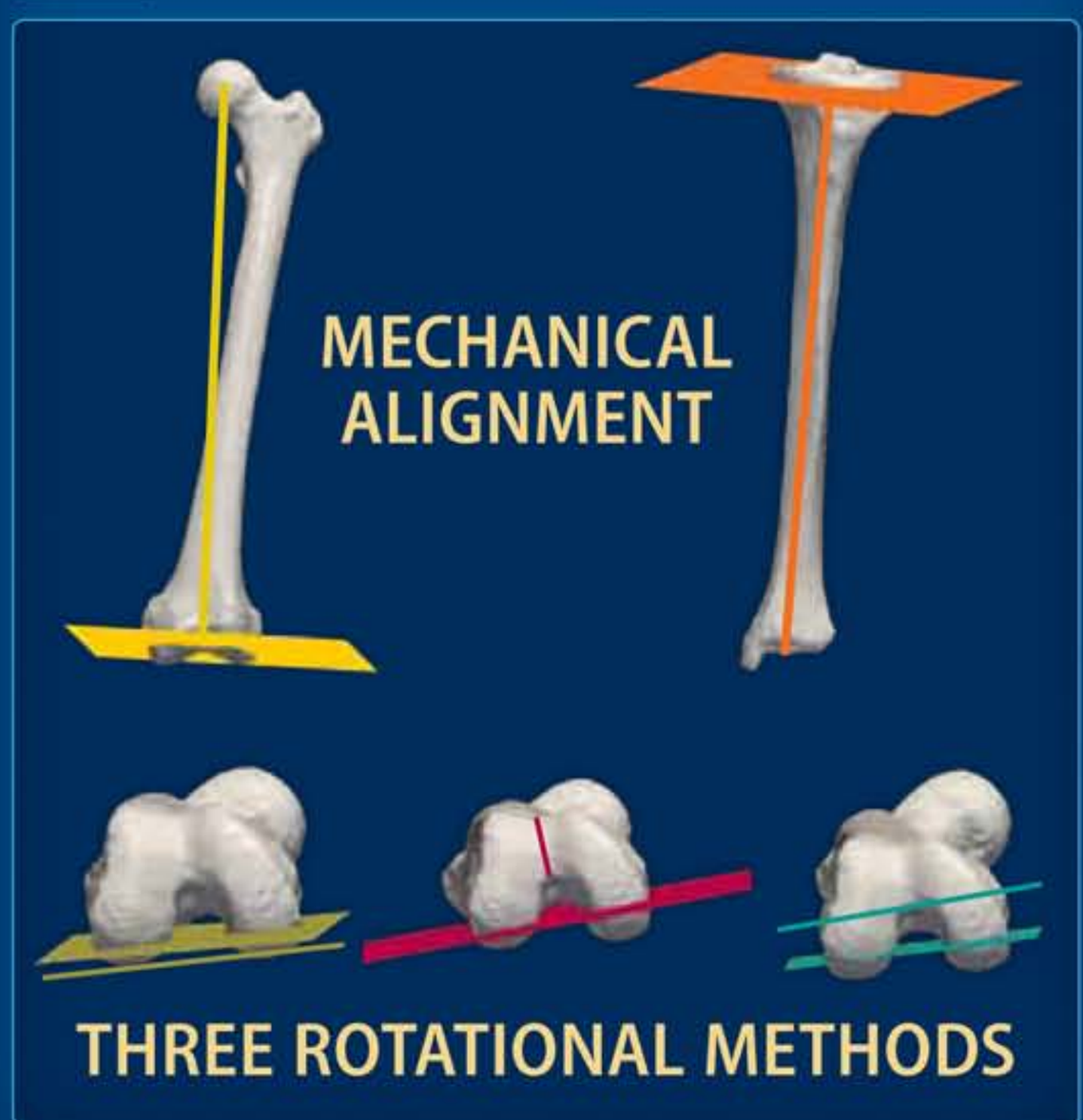

STUDY 1

How Does Limb Rotation and Flexion Contracture of the Knee Change Four Measurements of Coronal Alignment?

INTRODUCTION

Axial rotation of the limb and flexion contracture of the knee affect four measurements of coronal alignment[1-4]: limb, knee, femoral joint line, and tibial joint line alignment (Figure 1).

This study 1) defined a standard coronal projection of the limb that is perpendicular to the flexion-extension plane of the knee, and then 2) determined the combinations of limb rotation and flexion contracture that caused changes in the measurements of coronal alignment >1°; changes >1° were considered clinically unacceptable errors.

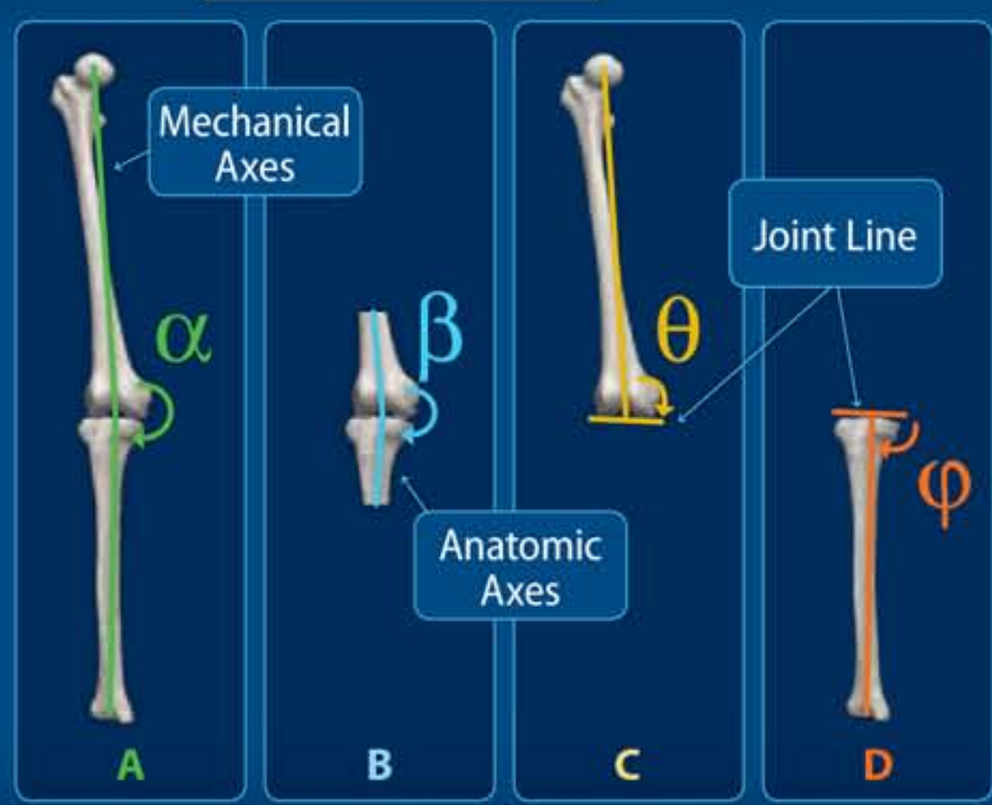

Figure 1. Four measurements of coronal alignment:

(A) Limb alignment $= (180-\alpha)°$

(B) Knee alignment $= (180-\beta)°$

(C) Femoral joint line alignment $= (90-\theta)°$

(D) Tibial joint line alignment $= (90-\varphi)°$

METHOD

1. Three-dimensional bone models created from computed tomography (CT) scans of fifty normal limbs were studied (Fig 2A).
2. Each limb was rotated into the standard coronal projection (Fig 2B).
3. Each knee was flexed from 0° to 40° in 5° increments to simulate a range of flexion contractures. For each flexion contracture, the limb was rotated from –30° internal rotation (IR) (–) to 30° external rotation (ER) (+) in 5° increments.
4. For each combination of rotation and flexion contracture, the change in each of the four measurements of coronal alignment (Fig 1) from the standard coronal projection of the limb was computed. The mean absolute change (i.e. without regard as to whether the change was + or –) of all limbs was plotted (Fig 3).

Figure 2.

(A) Three-dimensional bone model.

(B) Posterior view of the femur shows the plane (orange rectangle) that defines the orientation of the standard coronal projection. The plane is constructed tangent to the most posterior points on the femoral condyles (1, 2) and greater trochanter (3) and is perpendicular to the flexion-extension plane of the knee.

RESULTS

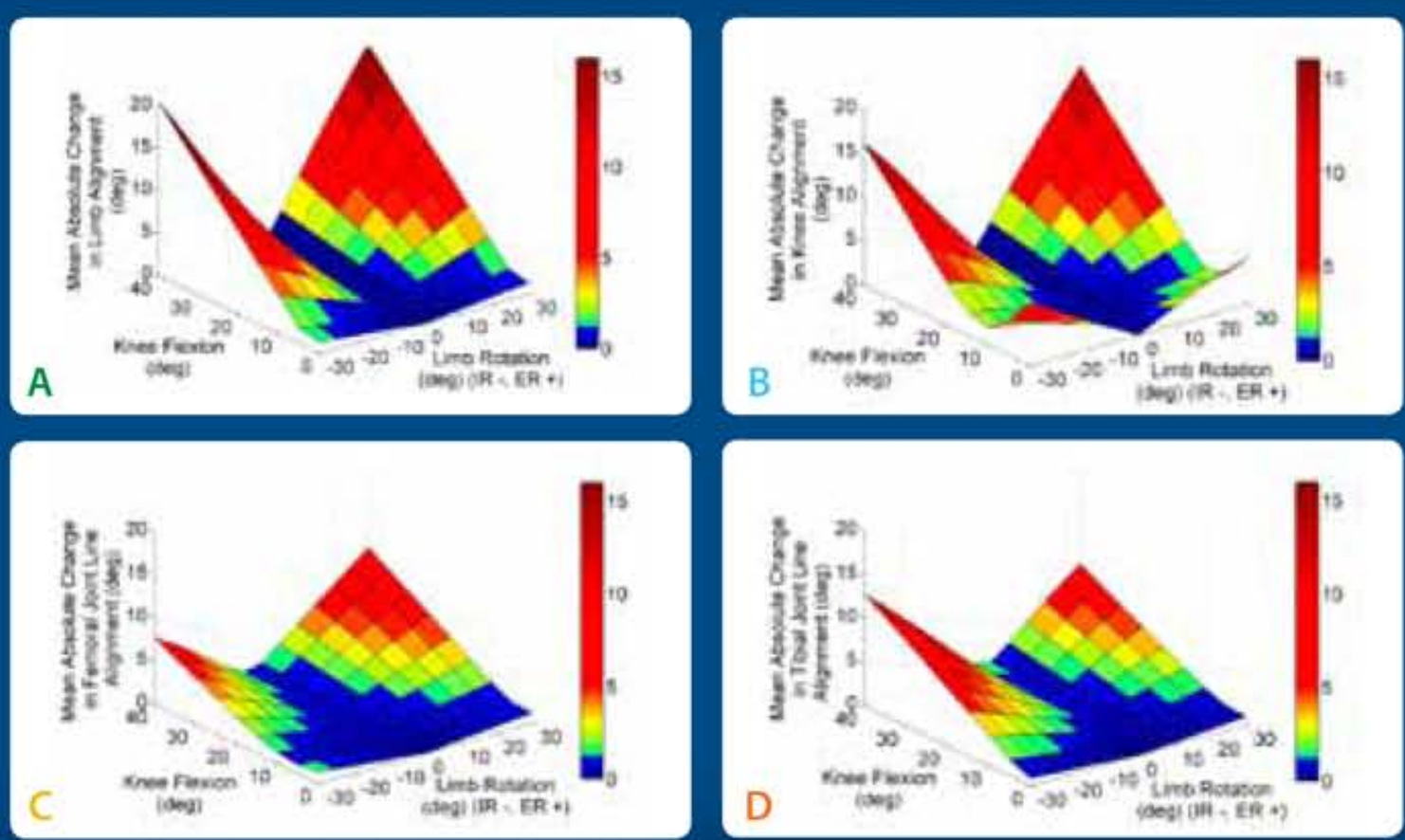

Figure 3.

Surface plots show the mean absolute change in each of the four measurements of coronal alignment: (A) limb alignment, (B) knee alignment, (C) femoral joint line alignment, and (D) tibial joint line alignment for each combination of limb rotation and knee flexion contracture.

Squares of colors other than blue indicate a change in measurement of >1°, which was considered a clinically unacceptable error.

DISCUSSION and CONCLUSION

If the intention is to avoid a clinically unacceptable error when using a single radiograph of the limb to measure limb, knee, femoral joint line, and tibial joint line alignment, then limb rotation must be within 5° of the standard coronal projection for flexion contractures up to 40°. The pitfalls for not standardizing limb rotation are an incorrect assessment of TKA alignment and an incorrect plan of femoral and tibial osteotomies.

1. Siu, D., T. D. Cooke, et al. (1991). Invest Radiol. 26(1): 71-77.
2. Wright, J. G., N. Treble, et al. (1991). J Bone Joint Surg Br. 73(5): 721-723.
3. Lonner, J. H., M. T. Laird, et al. (1996). Clin Orthop Relat Res. (331): 102-106.
4. Brouwer, R. W., T. S. Jakma, et al. (2007). J Knee Surg. 20(3): 210-215.

Scientific Exhibit 20, AAOS 2012 | www.bme.ucdavis.edu/hull/

STUDY 2

How Frequently Do Three Radiographic Methods for Rotationally Aligning the Limb Change the Measurements of Coronal Alignment?

INTRODUCTION

Radiographers often choose one of three methods to rotationally align the limb: patella forward[1], tibial tubercle forward[2], or foot forward[3]. This study determined, for these three radiographic methods for rotationally aligning the limb, the frequencies of >1° changes in the measurements of coronal alignment from the standard coronal projection; changes >1° were considered clinically unacceptable errors.

METHOD

1. Three-dimensional bone models of fifty normal limbs were rotated into the standard coronal projection (refer to Study 1, Figs 2A, B).
2. A 15° flexion contracture, a common deformity in the arthritic knee[4,5], was simulated.
3. Each limb was aligned with the patella forward, the tibial tubercle forward, and the foot forward methods (Fig 4).
4. For each radiographic method, the change in each of the four measurements of coronal alignment from the standard coronal projection of the limb was computed (Fig 5).

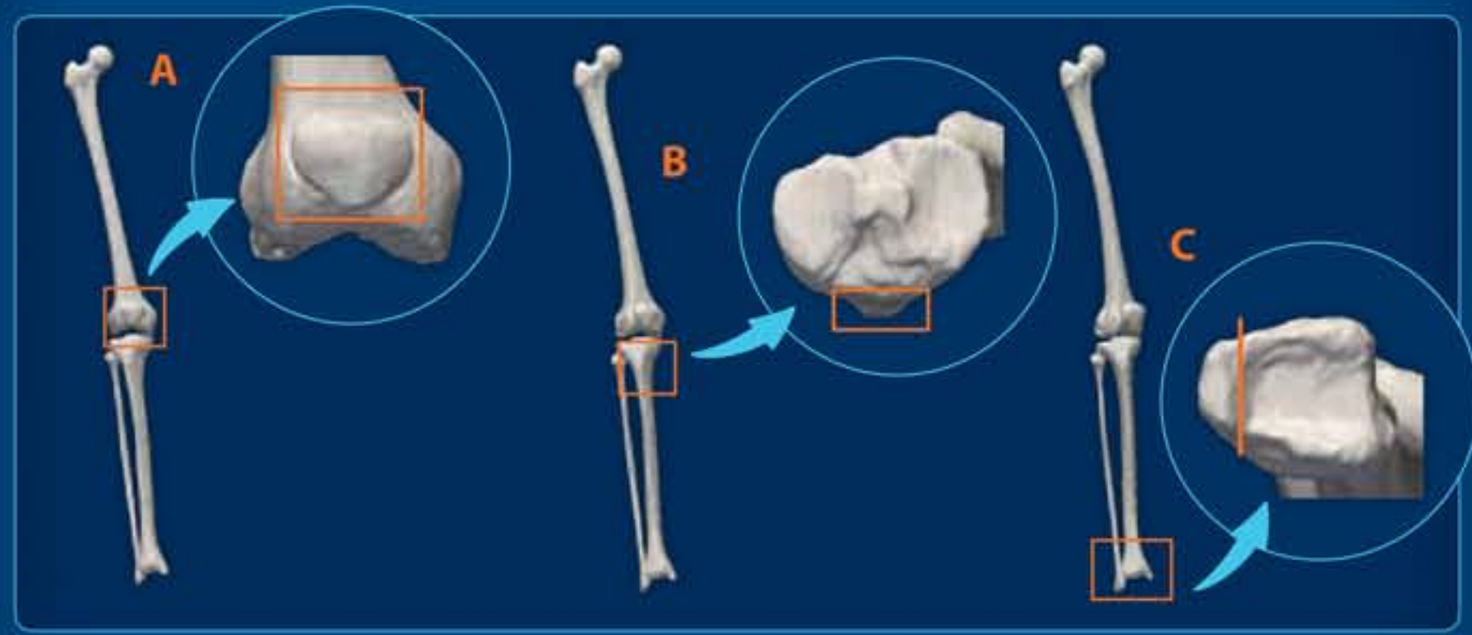

Figure 4. (A) The patella forward method orients the limb by centering the patella medial-lateral on the distal femur. (B) The tibial tubercle forward method orients the limb by facing the center of the tibial tubercle anterior. (C) The foot forward method orients the limb by aligning a line on the articular surface of the medial malleolus anterior. Notice the changes in the position of the patella on the distal femur, which indicates the projection of limbs A, B, and C are different.

RESULTS

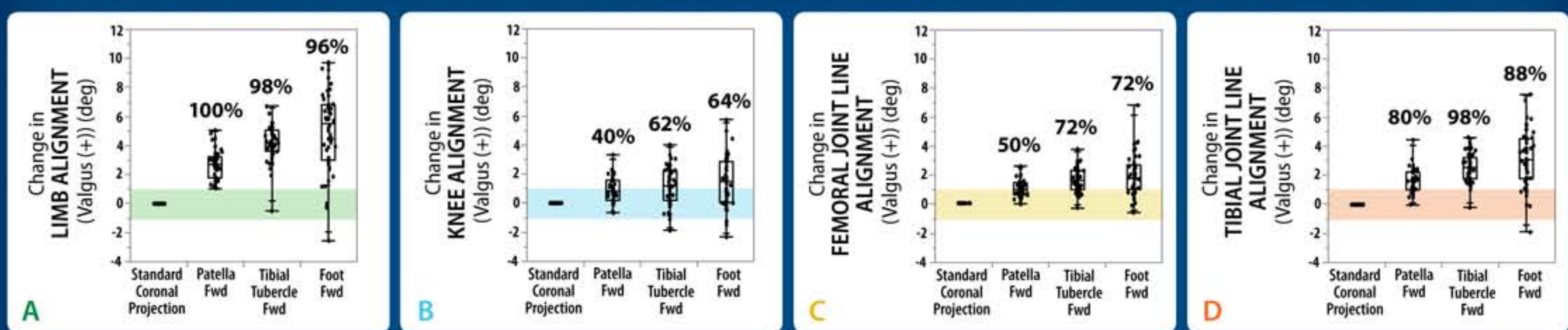

Figure 5. Box plots show the changes in the measurements of (A) limb, (B) knee, (C) femoral joint line, and (D) tibial joint line alignment from the standard coronal projection of the limb for each radiographic method.

The percentages indicate the frequency that each radiographic method caused a clinically unacceptable error in measurement.

DISCUSSION and CONCLUSION

All three radiographic methods frequently caused a clinically unacceptable error in each measurement of coronal alignment ranging from 40–100%. Accordingly, measurements from the three radiographic methods are unreliable, and the standard coronal projection of the limb should be used during imaging[6,7].

1. Moreland, J. R., L. W. Bassett, et al. (1987). J Bone Joint Surg Am. 69A(5): 745-749.
2. Hsu, R. W., S. Himeno, et al. (1990). Clin Orthop Relat Res. (255): 215-227.
3. Skytta, E. T., M. Lohman, et al. (2009). Scand J Surg. 98(4): 250-253.
4. Saito, T., R. Takeuchi, et al. (2003). J Arthroplasty. 18(5): 612-618.
5. Bellemans, J., H. Vandenneucker, et al. (2006). Clin Orthop Relat Res. 452: 78-82.
6. Cooke, T. D. V., R. A. Scudamore, et al. (1991). J Bone Joint Surg Br. 73(5): 715-720.
7. Brouwer, R. W., T. S. Jakma, et al. (2003). Acta Orthop Scand. 74(5): 565-568.

STUDY 3

How Frequently Does the Classification of Limb and Knee Alignment as Either 'In-Range', Varus 'Outlier', or Valgus 'Outlier' Disagree in a Normal Limb?

INTRODUCTION

Surgeons use one of two radiographic views for classifying the alignment of a TKA as either 'in-range', varus 'outlier', or valgus 'outlier'. Those with access to a full-leg radiograph of the limb may choose this view, while others choose the shorter radiograph of the knee. Because this classification is used as a predictor for the long-term success of TKA[1,2], this study determined how frequently the 'in-range', varus 'outlier', and vagus 'outlier' classifications of the limb and knee disagreed in a normal limb.

METHOD

1. Three-dimensional bone models of fifty normal limbs were rotated into the standard coronal projection (refer to Study 1, Fig 2A, B).
2. The limb and knee alignments (Fig 6A, B) were measured and then classified as 'in-range', varus 'outlier', or valgus 'outlier' (Table 1).
3. The frequencies of disagreement and agreement between the classifications of the limb and knee were computed for each specimen (Table 2).

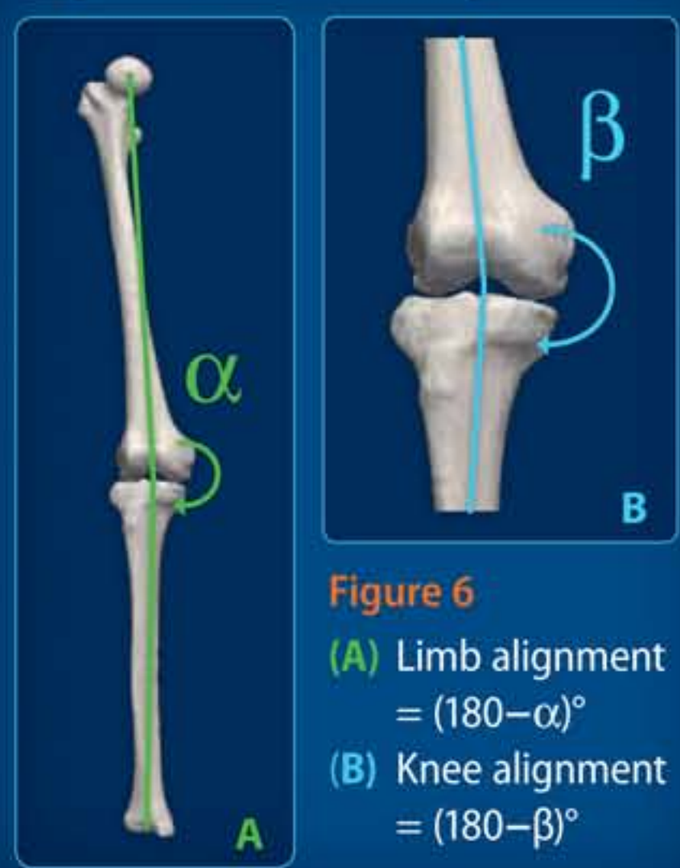

Figure 6
(A) Limb alignment = (180−α)°
(B) Knee alignment = (180−β)°

Table 1. Definition of 'in-range', varus 'outlier', and valgus 'outlier' for the limb and knee[3].

	LIMB	KNEE
'In-Range'	3° varus to −3° valgus	−2° to −8° valgus
Varus 'Outlier'	>3° varus	>−2° valgus
Valgus 'Outlier'	<−3° valgus	<−8° valgus

RESULTS

Table 2. The frequency of each combination of limb and knee classification is noted in each cell as a percentage. Orange cells show combinations where the classifications of the limb and knee disagreed. Two bone models show examples of two of the six combinations of disagreement (orange arrows).

KNEE ALIGNMENT	LIMB ALIGNMENT: Varus 'Outlier' (>3° varus)	'In-range' (3° varus to −3° valgus)	Valgus 'Outlier' (<−3° valgus)
Varus 'Outlier' (>−2° valgus)	2%	2%	0%
'In-range' (−2° to −8° valgus)	4%	72%	2%
Valgus 'Outlier' (<−8° valgus)	2%	10%	6%

DISCUSSION and CONCLUSION

In 20% of normal limbs, the 'in-range', varus 'outlier', and valgus 'outlier' classifications of limb and knee alignment disagreed. Because these classifications are used to predict the long-term outcome of TKA[1,2], the study of the frequency of disagreement between the classifications of the limb and knee is warranted in patients with TKA.

1. Jeffery, R. S., R. W. Morris, et al. (1991). J Bone Joint Surg Br. 73(5): 709.
2. Fang, D. M., M. A. Ritter, et al. (2009). J Arthroplasty. 24(6): 39-43.
3. Nunley, R., B. Ellison, et al. Clin Orthop Relat Res. Online First: 20 Dec 2011.

Scientific Exhibit 20, AAOS 2012 | www.bme.ucdavis.edu/hull/

STUDY 4

How Frequently Do Two Gap Balancing Methods Change the Joint Lines and Limb Alignment from Normal in TKA?

INTRODUCTION

When placing TKA components, changing the angle of the joint lines from normal has the undesirable consequence of changing the kinematics of the knee and limb from normal[1-3]. This study determined, for two gap-balancing alignment methods in TKA, the frequencies and magnitudes of 1) changes in the angles of the distal femoral joint line, the posterior femoral joint line, and the tibial joint line from normal, and 2) the change in limb alignment from normal.

METHOD

1 Two gap balancing methods (I and II) were simulated on three-dimensional models of fifty normal limbs that were rotated into the standard coronal projection (Figs 7, 8).

2 The changes in the angles of the distal and posterior femoral joint lines, the tibial joint line, and limb alignment from normal were measured (Table 3).

Figure 7: Illustration of Method I

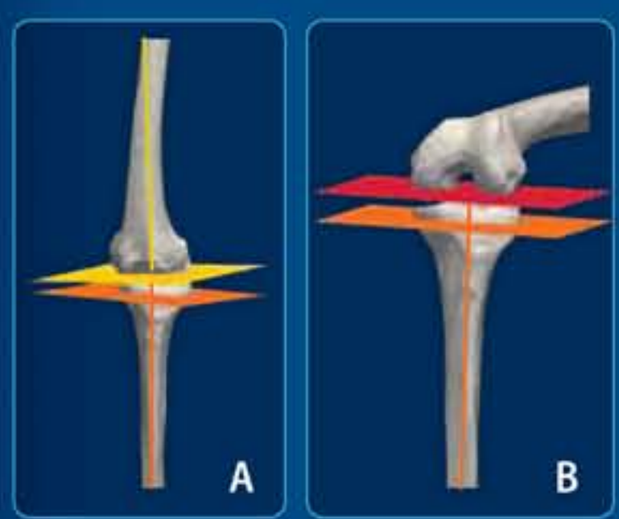

(A) The plane of the distal femoral cut (yellow) and the plane of the tibial cut (orange) were made perpendicular to the femoral mechanical axis (yellow) and tibial mechanical axis (orange) respectively. The tibia was then rotated until the cut planes were parallel. (B) The femur was flexed 90°, and the plane of the posterior femoral cut (red) was made parallel to the plane of the tibial cut.

Figure 8: Illustration of Method II

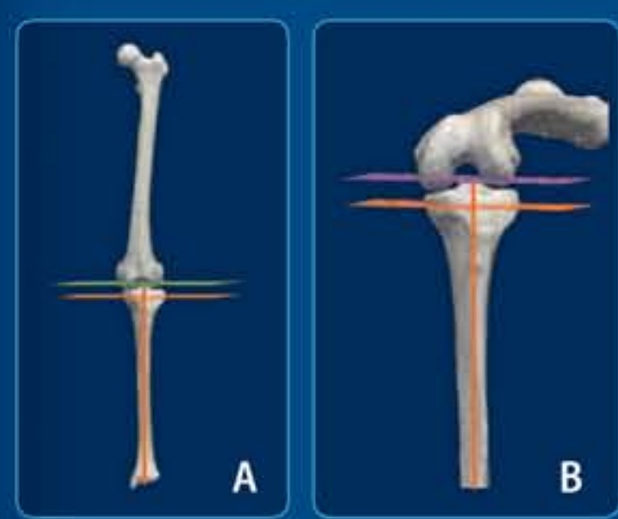

(A) The plane of the tibial cut (orange) was made perpendicular to the tibial mechanical axis (orange). The plane of the distal femoral cut (green) was made parallel to the plane of the tibial cut. (B) The femur was flexed 90°, and the plane of the posterior femoral cut (purple) was made parallel to the plane of the tibial cut.

RESULTS

Table 3. Summary of changes in joint lines and limb alignment ≥ 1° and ≥ 3° with use of two gap balancing methods. Positive values indicate either a valgus or an external rotation change.

Change in Angular Measurement from Normal		Distal Femoral Joint Line		Posterior Femoral Joint Line		Tibial Joint Line		Limb Alignment	
		≥ 1°	≥ 3°	≥ 1°	≥ 3°	≥ 1°	≥ 3°	≥ 1°	≥ 3°
Method I	% of Subjects	82%	46%	88%	62%	82%	60%	68%	22%
	Range (°)	[–8 to 8]		[–10 to 7]		[–8 to 8]		[–7 to 5]	
Method II	% of Subjects	82%	60%	86%	66%	82%	60%	0%	0%
	Range (°)	[–8 to 8]		[–10 to 7]		[–8 to 8]		0	

DISCUSSION and CONCLUSION

The frequencies that both methods changed the distal femoral joint line, posterior femoral joint line, and the tibial joint line >3° from normal ranged from 46% to 66%. One advantage of Method II over Method I is that no ligament releases were required to balance the gaps. Three pitfalls from changing the distal and posterior femoral joint lines from normal are abnormal tibiofemoral kinematics[2], abnormal patellofemoral kinematics[3], and compromised knee function in some patients[4,5].

1. Eckhoff, D. G., J. M. Bach, et al. (2005). J Bone Joint Surg Am. 87(Supplement 2): 71-80.
2. Merican, A. M., K. M., Ghosh, et al. (2011). Knee Surg Sports Traumatol Arthrosc. Sep; 19(9): 1479-87.
3. Berger, R. A., L. S. Crossett, et al. (1998). Clin Orthop Relat Res. 356: 144-153.
4. Smith, C. K., J. A. Chen, et al. (2010). J Arthroplasty. 25(7): 1137-1142.
5. Bellemans, J., S. Banks, et al. (2002). J Bone Joint Surg Br. 84(1): 50.

STUDY 5

How Frequently Does Mechanical Alignment with Three Rotational Methods Change Joint Lines, Change Limb Alignment, and Cause Instability in TKA?

INTRODUCTION

Changing angles of the distal and posterior femoral joint lines, the tibial joint line, and the limb alignment from normal can alter knee kinematics, soft-tissue balance, and cause knee instability in TKA[1-3]. This study determined, for three rotational methods for aligning the femoral component in mechanically-aligned TKA , the frequencies and magnitudes of 1) changes in the varus-valgus (V-V) angle of the distal femoral joint line, the internal-external (I-E) angle of the posterior joint line, and the V-V angle of the tibial joint line from normal, 2) the change in limb alignment from normal, and 3) the occurrence of knee instability between 0° of extension and 90° of flexion.

METHOD

1. Three-dimensional bone models of fifty normal limbs were rotated into the standard coronal projection.
2. Three rotational methods for aligning the femoral component in mechanically-aligned TKA were simulated on each specimen (Figs 9-11).
3. The changes in the angles of the distal and posterior femoral joint lines, the tibial joint line, and limb alignment from normal were measured (Table 4).
4. In each compartment, the sum of the femoral and tibial resection thicknesses quantified the gap. When the difference between the medial and lateral gaps at a particular flexion angle exceeded 1mm, it was considered asymmetric. When the difference of the difference between medial and lateral gaps at 0° of extension and at 90° of flexion exceeded 1mm, it was considered unequal and represented knee instability (Fig 12).

Figure 9. The plane of the distal femoral cut (yellow) was perpendicular to the femoral mechanical axis with a minimum resection of 8mm. The thickness of the medial and lateral femoral bone resections was measured.

Figure 10. The plane of the tibial cut (orange) was perpendicular to the tibial mechanical axis with a minimum resection of 9mm. The medial and lateral thicknesses of the tibial bone resection were measured.

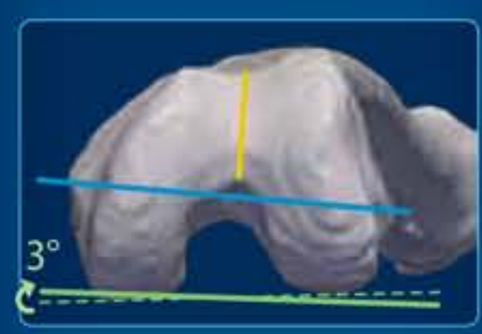

Figure 11. The plane of the posterior femoral cut was simulated for three methods for aligning the femoral component 1) parallel to the transepicondylar axis (TEA) (blue), 2) perpendicular to Whiteside's Line (yellow), and 3) 3° externally rotated from the posterior condylar axis (3° PC) (green).

RESULTS

Table 4.

Summary of changes in the angles of the joint lines and limb alignment ≥1° and ≥3°.

Change in Angular Measurement From Normal		TEA	Whiteside's Line	3° PC
Distal Femoral Joint Line	≥ 1°	84%		
	≥ 3°	50%		
Posterior Femoral Joint Line	≥1°	88%	94%	100%
	≥ 3°	66%	74%	100%
Tibial Joint Line	≥ 1°	82%		
	≥ 3°	60%		
Limb Alignment	≥ 1°	68%		
	≥ 3°	22%		

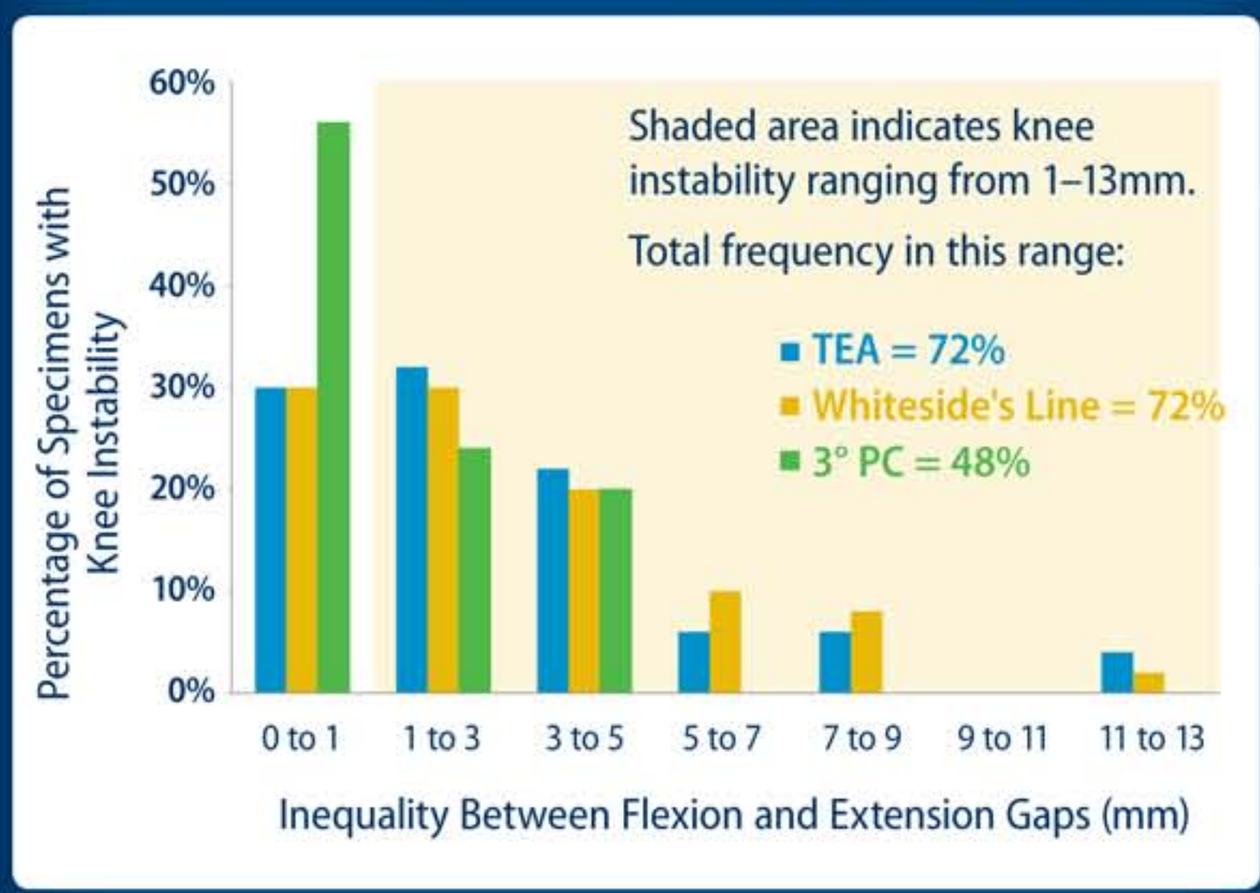

Figure 12.

Histogram of the inequality between flexion and extension gaps.

DISCUSSION and CONCLUSION

Mechanical alignment of a TKA with each of three methods for rotationally aligning the femoral component has pitfalls. Each method frequently yields substantial changes in the angle of all three joint lines and limb alignment from normal. Furthermore, these angular changes are sufficient in magnitude to cause unequal flexion and extension gaps which result in knee instability in 48% to 72% of the specimens. Consequently, each method disrupts the normal kinematics of the knee[1,4].

1. Eckhoff, D. G., J. M. Bach, et al. (2005). J Bone Joint Surg Am 87 Suppl. 2:71-80.
2. Berger, R. A., L. S. Crossett, et al. (1998). Clin Orthop Relat Res. 356:144-153.
3. Martin, J. W., L. A. Whiteside, (1990) Clin Orthop Relat Res. Oct; 259:146-56.
4. Merican, A. M., K. M. Ghosh, et al. (2011). Knee Surg Sports Traumatol Arthrosc. Sep; 19(9):1479-87.

SE 20

Take-Home Messages From the Five Studies

STUDY 1

How Does Limb Rotation and Flexion Contracture of the Knee Change Four Measurements of Coronal Alignment?

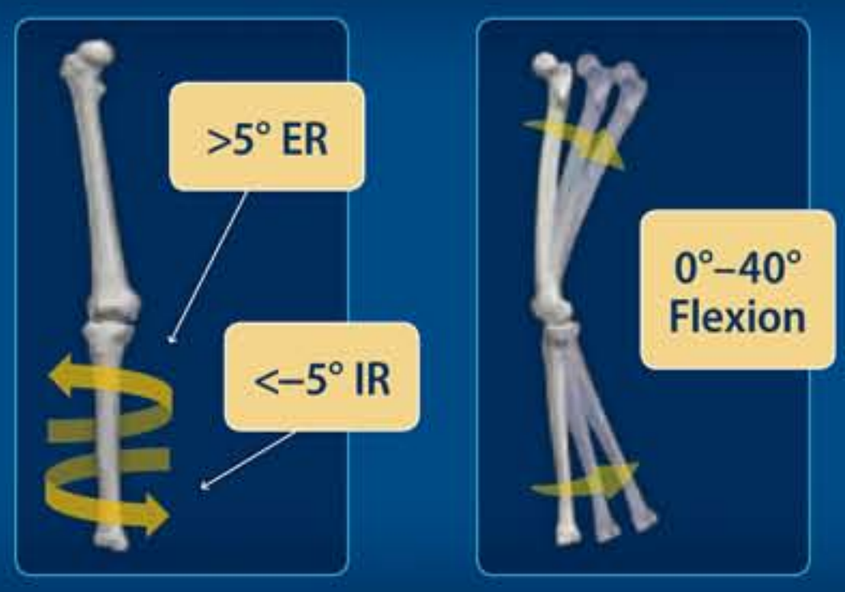

The limb rotation must be within 5° of the standard coronal projection for flexion contractures up to 40° to avoid clinically unacceptable errors (>1°) in the measurements of limb, knee, femoral joint line, and tibial joint line alignment.

STUDY 2

How Frequently Do Three Radiographic Methods for Rotationally Aligning the Limb Change the Measurements of Coronal Alignment?

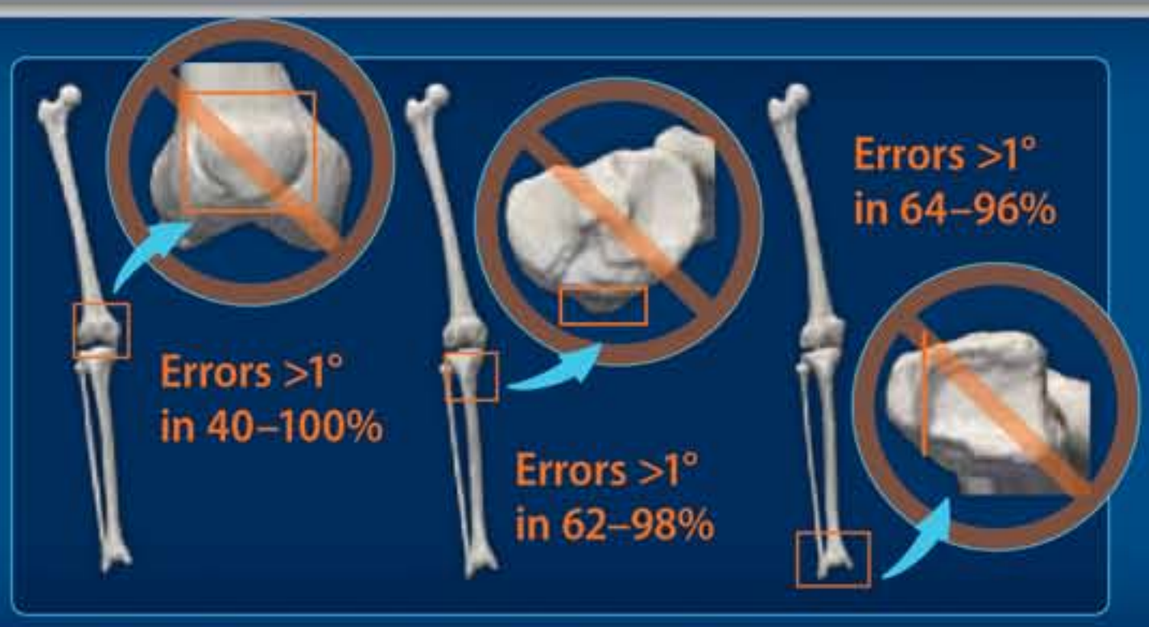

The standard coronal projection of the limb should be used during imaging because the patella forward, tibial tubercle forward, and foot forward methods frequently caused clinically unacceptable errors (>1°) in measurements of limb, knee, femoral joint line, and tibial joint line alignment.

STUDY 3

How Frequently Does the Classification of Limb and Knee Alignment as Either 'In-range', Varus 'Outlier', or Valgus 'Outlier' Disagree in a Normal Limb?

The 'in-range', varus 'outlier', and valgus 'outlier' classifications of limb and knee alignment disagreed in 20% of normal limbs which questions whether these classifications are useful in TKA.

STUDY 4

How Frequently Do Two Gap Balancing Methods Change the Joint Lines and Limb Alignment from Normal in TKA?

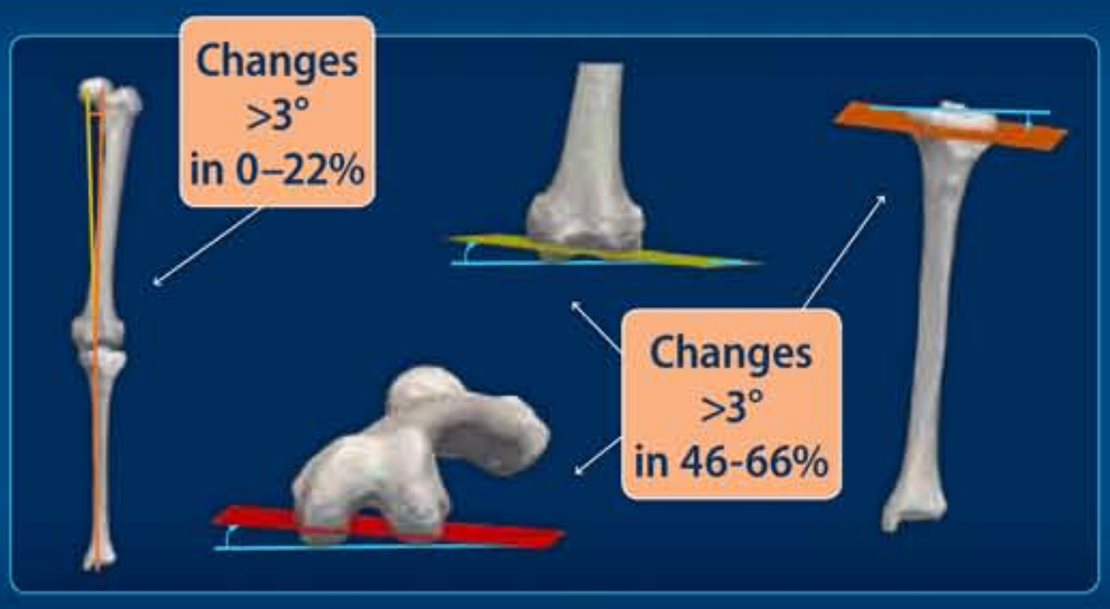

Both methods changed the distal femoral joint line, posterior femoral joint line, and the tibial joint line >3° from normal in 46% to 66% of specimens. Method I changed the limb alignment in 22% of specimens while Method II restored the limb alignment.

STUDY 5

How Frequently Does Mechanical Alignment with Three Rotational Methods Change Joint Lines, Change Limb Alignment, and Cause Instability in TKA?

All of the three rotational methods for aligning the femoral component in mechanically-aligned TKA frequently change the angles of all three joint lines and limb alignment from normal, which result in knee instability in 48% to 72% of the specimens.

ACKNOWLEDGEMENT

We would like to thank Stryker Orthopaedics for their support for this research.